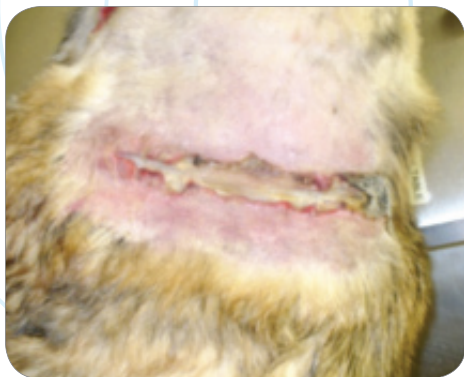

CASE STUDY

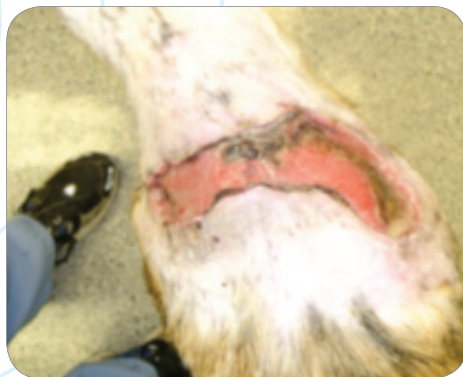Soft Tissue Trauma

K-LASER[™]
USA

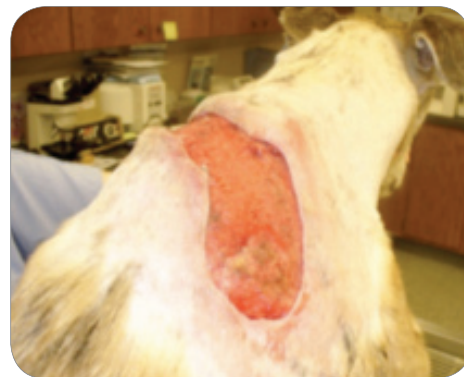1106 Harpeth Industrial Court
Franklin, TN 37064
866-595-7749 (v) • 615-261-3535 (f)
www.k-laserusa.com



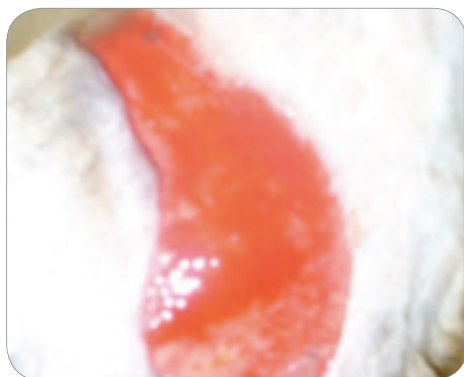MARCH 14



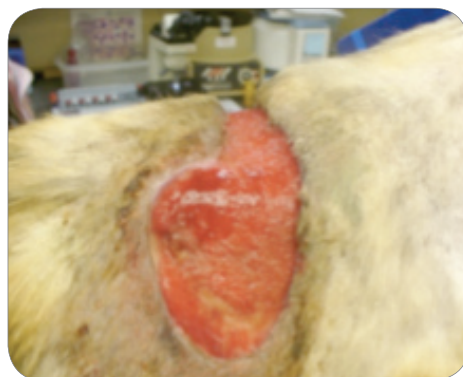
MARCH 18



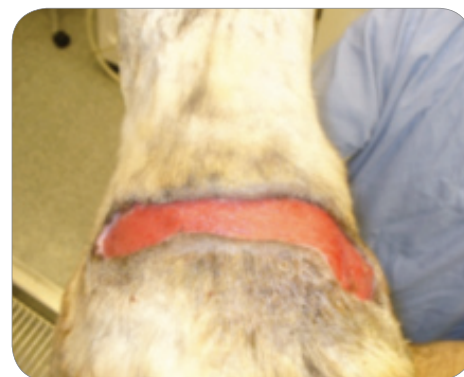MARCH 22



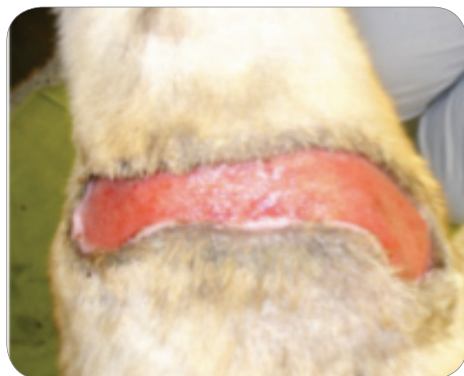MARCH 28



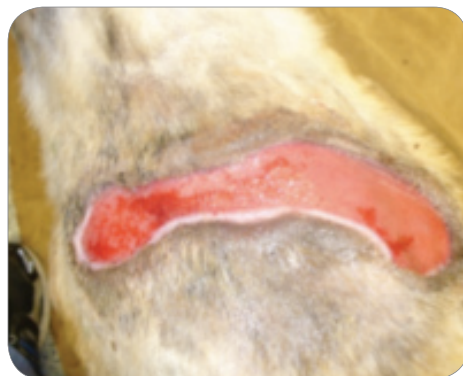APRIL 4



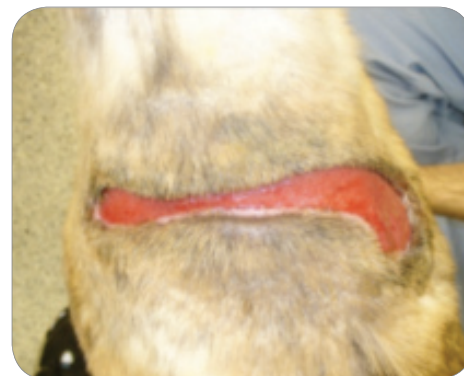APRIL 12



APRIL 23



APRIL 26



APRIL 30



Tucker, Greyhound

Presented March 10, 2010. Dog attack with extensive injuries

LOCATION: Back

DEVICE: K-Laser 6d

PROTOCOL: Soft Tissue Trauma

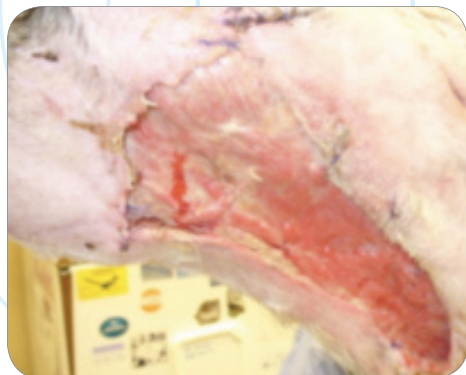
CASE AND PHOTOS COURTESY OF CALVIN CLEMENTS, DVM, CCRP KYLE KOLVA, CVT, CCRP AT PALMYRA ANIMAL HOSPITAL, PALMYRA, PA

CASE STUDY

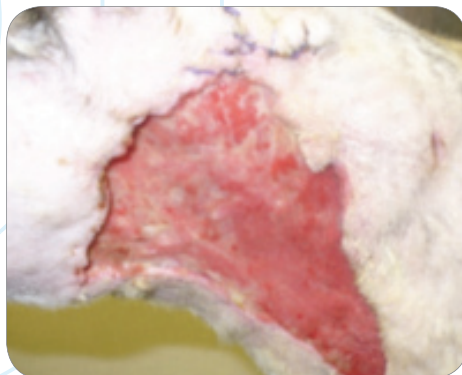
Soft Tissue Trauma

K-LASER[™]_{USA}

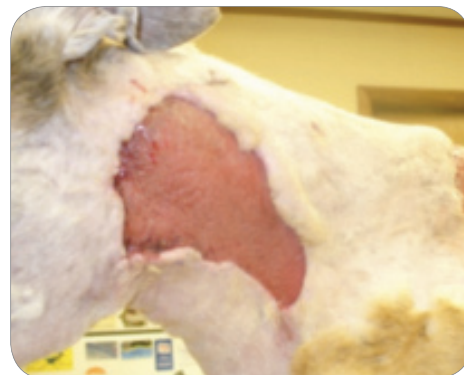1106 Harpeth Industrial Court
Franklin, TN 37064
866-595-7749 (v) • 615-261-3535 (f)
www.k-laserusa.com



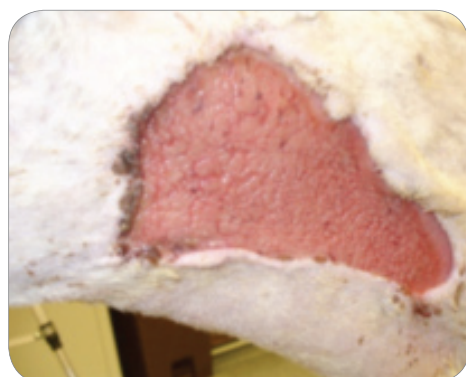
MARCH 10



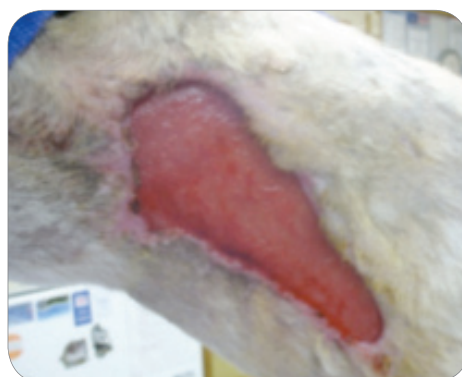MARCH 14



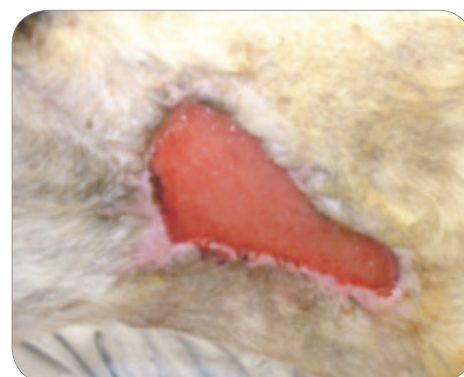
MARCH 22



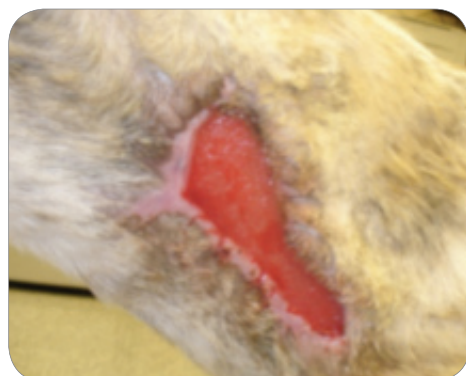
MARCH 24



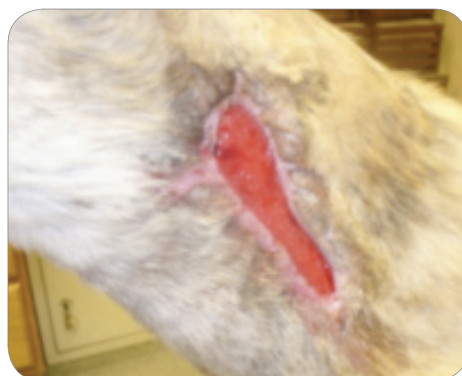APRIL 4



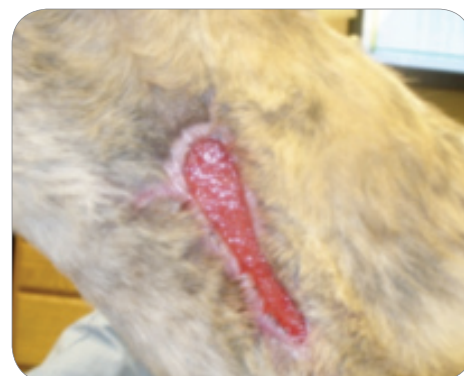APRIL 12



APRIL 18



APRIL 26



APRIL 30



Tucker, Greyhound

Presented March 10, 2010. Dog attack with extensive injuries

LOCATION: Neck, Left Side

DEVICE: K-Laser 6d

PROTOCOL: Soft Tissue Trauma

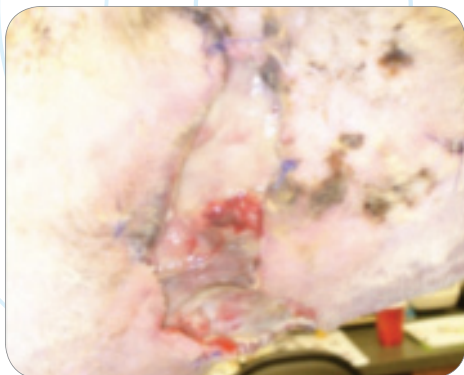CASE AND PHOTOS COURTESY OF CALVIN CLEMENTS, DVM, CCRP KYLE KOLVA, CVT, CCRP OF PALMYRA ANIMAL HOSPITAL, PALMYRA, PA

CASE STUDY

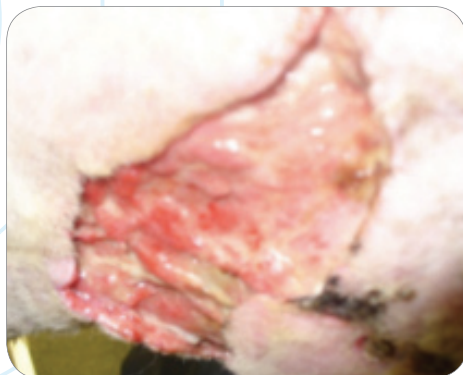
Soft Tissue Trauma

K.LASER[™]_{USA}

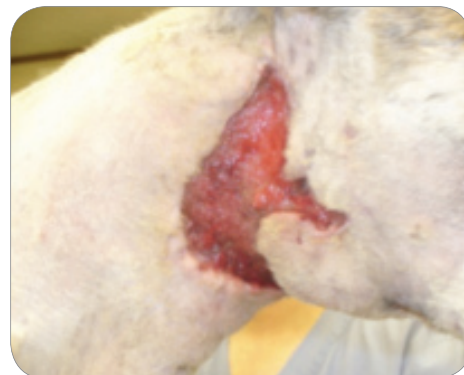1106 Harpeth Industrial Court
Franklin, TN 37064
866-595-7749 (v) • 615-261-3535 (f)
www.k-laserusa.com



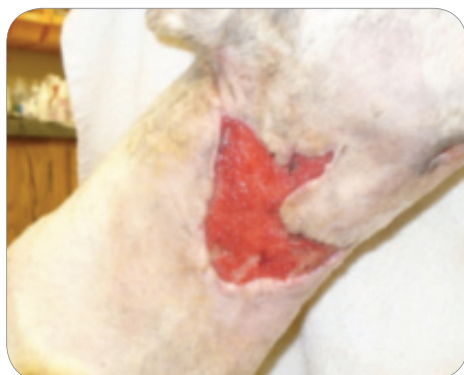MARCH 10



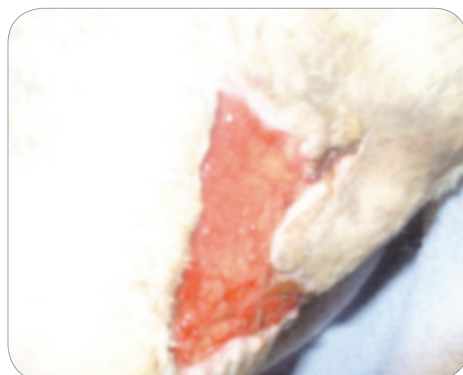
MARCH 14



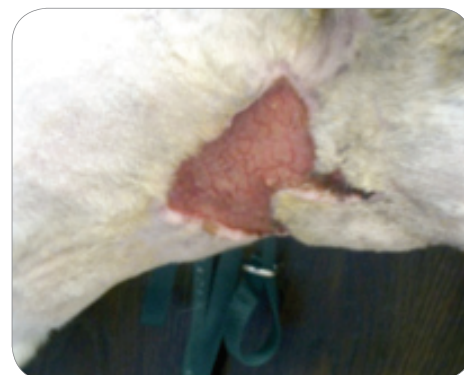MARCH 22



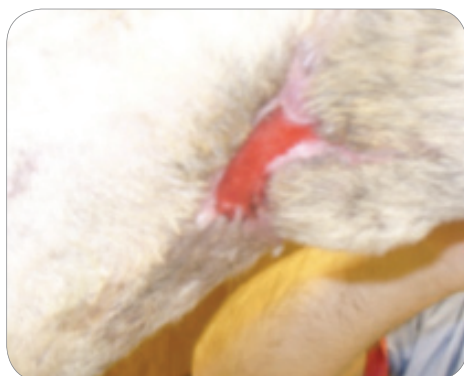
MARCH 24



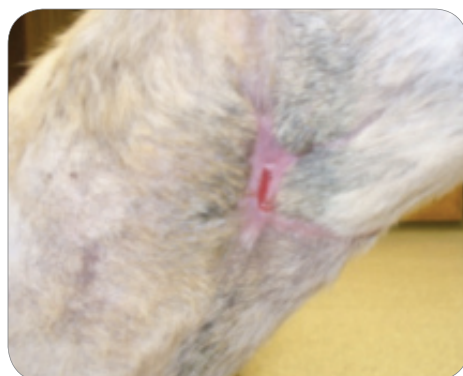MARCH 29



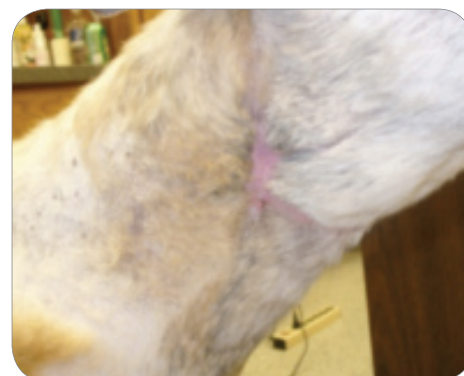APRIL 5



APRIL 12



APRIL 23



APRIL 26



Tucker, Greyhound

Presented March 10, 2010. Dog attack with extensive injuries

LOCATION: Neck, Right Side

DEVICE: K-Laser 6d

PROTOCOL: Soft Tissue Trauma

CASE AND PHOTOS COURTESY OF CALVIN CLEMENTS, DVM, CCRP KYLE KOLVA, CVT, CCRP OF PALMYRA ANIMAL HOSPITAL, PALMYRA, PA